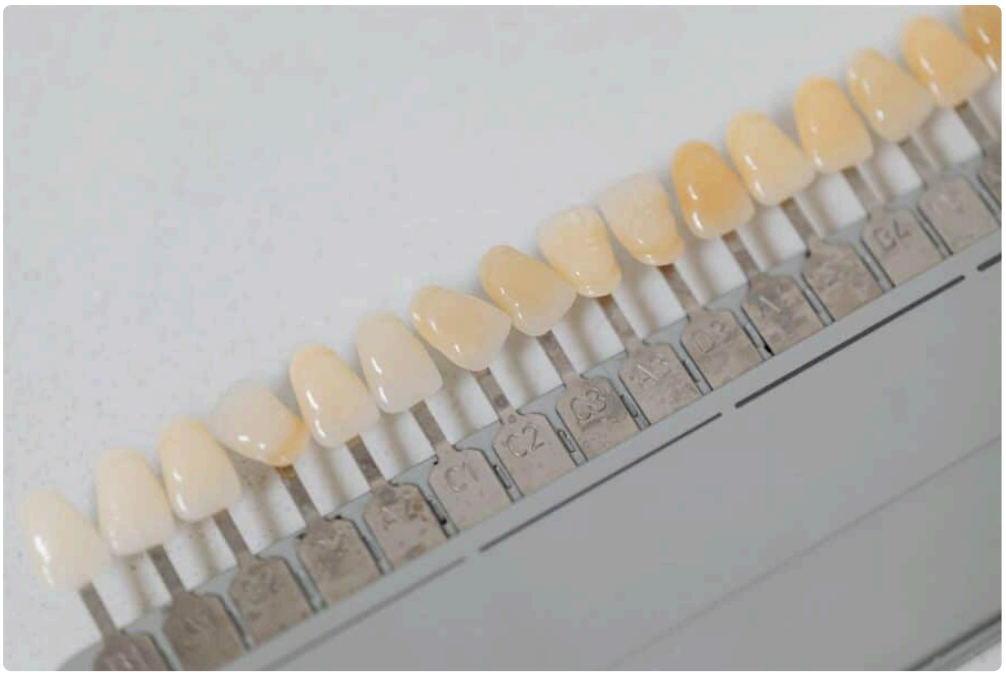
A2
C1
C2
C3
A3
D3
A1
B2
B4

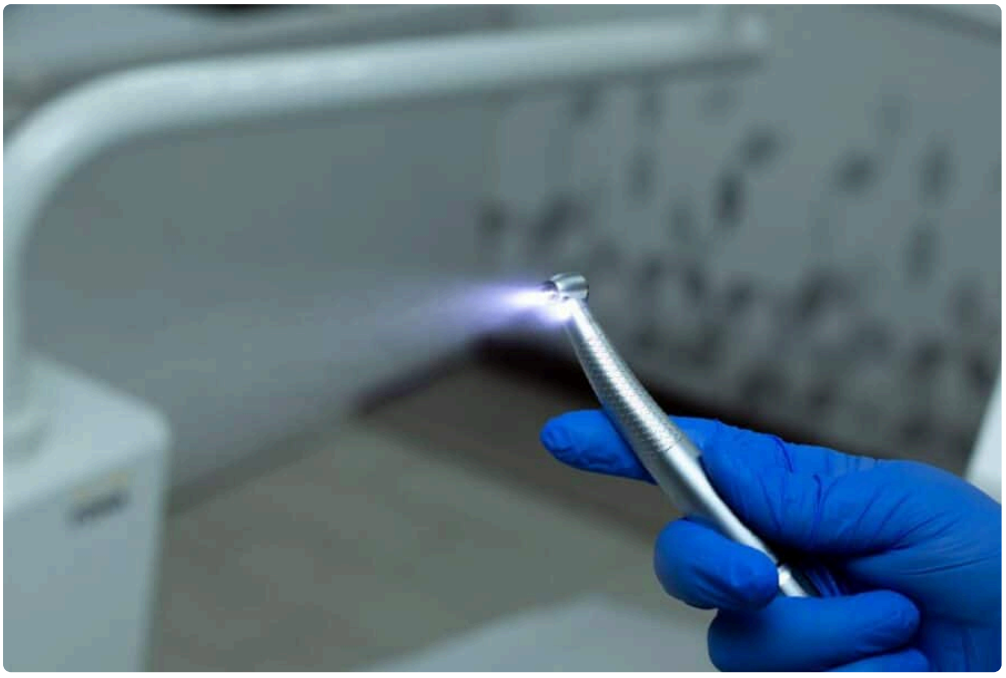

A chipped tooth has a way of turning an ordinary day into a stressful one. It can happen while biting into something hard, taking an elbow during a pickup basketball game, or waking up and realizing that a weak old filling finally gave way. Some chips are small and mostly cosmetic. Others expose sensitive inner tooth structure, create sharp edges that cut the tongue, or signal a deeper fracture that can worsen by the hour.

That uncertainty is exactly why it makes sense to contact an **Emergency Dentist Santa Clarita, CA** patients can reach quickly. When a tooth breaks, timing matters. Even when pain seems manageable, the damage may be more serious than it looks in the bathroom mirror. A prompt exam can reduce discomfort, protect the remaining tooth, and often make the repair simpler than it would be if you waited several days.

Dental emergencies do not always look dramatic. A person may walk around with a chipped molar for a weekend because there is no swelling and the ache comes and goes. By Monday, chewing on that side becomes impossible, cold water sends a jolt through the jaw, and the fracture has deepened enough to threaten the nerve. That is a familiar pattern in emergency dental care. What starts as “just a chip” can become a root canal or extraction problem if the tooth is left unprotected.

Not every chip feels urgent, but many deserve same-day attention

A front tooth chipped on a coffee mug tends to get immediate attention because it is visible. A back tooth is easier to ignore, especially if there is no bleeding. From a clinical standpoint, visibility does not tell you much about severity. The real concerns are how much tooth structure was lost, whether the crack extends below the gumline, whether the nerve is irritated, and whether your bite is now placing stress on a weakened tooth.

A small enamel chip may only need polishing or cosmetic bonding. A larger break may require a filling, an inlay, a crown, or in some cases more advanced treatment. If the chip happened around an old filling or crown, the tooth may already have been compromised before the accident. That changes the repair options. Teeth that have had previous root canals can be especially brittle, which is why a modest-looking fracture sometimes turns into a full cusp break.

Pain is also an imperfect guide. Some serious fractures hurt very little at first. Others are intensely painful because dentin is exposed, even though the long-term prognosis is quite good once the tooth is sealed. The safest assumption is simple: if a tooth has broken, get it evaluated promptly.

What causes a tooth to chip in the first place

People often think of trauma first, and direct impact is certainly a common cause. Sports injuries, slips on hard flooring, bike accidents, and contact to the face can all chip or crack teeth. But many broken teeth happen in quieter, less memorable ways.

Biting down on ice, popcorn kernels, olive pits, hard candy, and even crusty artisan bread can be enough if the tooth already has a weak spot. Large fillings leave less natural tooth structure to absorb force. Untreated decay hollows out a tooth from the inside. Clenching and grinding, especially during sleep, can create microscopic cracks over time until one day a cusp finally shears off. Acid erosion, age-related wear, and enamel defects also play a role.

That matters because the cause affects treatment. A clean chip on a healthy front tooth is one kind of repair. A fractured molar with a history of decay and nighttime grinding is another. A skilled emergency dentist is not just patching what broke, but figuring out why it broke so the same tooth, or the one next to it, does not fail again a few months later.

The first hour after the chip

Those first minutes matter more than most people realize. A calm response can lower the odds of added damage before you reach the dental office.

1. Rinse your mouth gently with warm water to clear debris and check whether there is bleeding.
2. If swelling is starting, place a cold compress against the outside of the cheek for short intervals.
3. Save any tooth fragment you can find, especially if the break is recent and clean.
4. Cover a sharp edge with dental wax or sugar-free gum if it is cutting your lip or tongue.
5. Call an emergency dental office right away, describe the injury, the pain level, and whether the tooth is loose.

There are also a few things worth avoiding. Do not chew on the injured side. Do not test the tooth repeatedly with your tongue. Do not place aspirin directly on the gum, a common home remedy that can irritate soft tissue. If you need pain relief and it is medically appropriate for you, over-the-counter medication may help, but it is not a substitute for an exam.

If the chip resulted from a blow to the face, pay attention to the surrounding injuries too. Difficulty opening the mouth, jaw misalignment, dizziness, heavy bleeding, or signs of concussion raise the stakes and may call for medical evaluation along with dental care.

What the dentist needs to know when you call

The quality of the phone call often shapes how quickly and effectively the office can help. A strong emergency team will ask focused questions because the details matter. Was the tooth chipped while eating, from a fall, or during sports? Is there pain with cold air, hot drinks, or biting pressure? Are you seeing pink or red tissue inside the tooth? Is the tooth loose? Is a crown or filling involved? Did the injury happen today or have symptoms been building?

In my experience, patients tend to underreport one thing and overreport another. They underreport bite changes, saying the tooth “feels a little off,” when in fact it is hitting first every time they close. They overreport the visual drama of jagged enamel on a front tooth, even when the tooth itself is structurally stable. Both pieces of information matter, but bite interference often predicts future trouble if it is not corrected.

This is where contacting an **Emergency Dentist Santa Clarita, CA** residents trust can make a practical difference. Offices that handle same-day emergencies regularly know how to triage. They can tell when a patient can be seen later in the day, when a tooth needs immediate protection, and when the injury suggests a deeper fracture that may require more involved treatment.

How dentists decide whether it is a chip, a crack, or something more serious

Patients use the words chip, crack, break, and fracture almost interchangeably. Dentistry gets more specific because treatment depends on the pattern.

A superficial enamel chip affects the outer shell and may need only smoothing or cosmetic repair. A larger fracture can expose dentin, the softer layer beneath enamel, which often causes temperature sensitivity and tenderness. If the damage extends into the pulp, where the tooth nerve and blood supply live, the pain can become sharp, throbbing, or spontaneous. That is when root canal treatment enters the conversation.

Then there are cracks. Some run vertically and are hard to see without magnification or special lighting. A cracked tooth may look nearly normal and still cause intense pain when chewing. Patients often describe it as a zing on release, not on pressure. That detail can be clinically useful. A crack that reaches below the gumline or splits the tooth into separate segments carries a much worse prognosis than a simple chip.

X-rays help, but they do not show everything. A dentist may also use bite tests, transillumination, percussion, periodontal probing, and close visual inspection. Sometimes the truth only becomes clear after the damaged restoration is removed and the underlying structure is exposed. Good emergency care often means stabilizing the tooth first, then confirming the long-term plan once inflammation settles and visibility improves.

The most common treatments after a chipped tooth

The repair depends on the size and location of the damage, whether the tooth is in the smile line, how the bite loads that area, and whether the nerve is involved. There is no one-size-fits-all answer, and that is a good thing. Conservative treatment is preferable when it will hold up. More extensive treatment is justified when it protects a vulnerable tooth from failing again.

For small chips on front teeth, cosmetic bonding is a common fix. Tooth-colored composite can restore shape and blend well when done carefully. In the right case, it is efficient *Emergency Dentist Santa Clarita, CA* and attractive. The trade-off is durability. Bonding can chip again, especially on incisal edges in patients who grind or bite pens, nails, or packaging.

For medium-sized breaks, especially where chewing force is higher, a filling or bonded buildup may restore function. If a larger portion of the tooth is missing, a crown often provides better long-term protection. Crowns are especially useful for molars with fractured cusps, teeth with big old fillings, and teeth that have already lost a lot of structure over the years.

If the break reaches the pulp or the nerve becomes irreversibly inflamed, root canal therapy may be necessary before the tooth is rebuilt. Many patients hear “root canal” and assume the tooth is doomed. Not necessarily. In a lot of cases, the root canal removes the pain source and allows the remaining tooth to be reinforced with a core and crown. The key is whether there is enough healthy structure left to support the restoration.

Some teeth cannot be predictably saved. That is hard news, but it is sometimes the most honest answer. A split tooth, severe fracture below the gumline, or damage extending into the root may leave extraction as the

soundest option. Even then, emergency dental care is still valuable because it controls pain, prevents infection, and lays out the next step, whether that means an implant, bridge, or another replacement plan.

Signs the chip may be more urgent than it looks

A chipped tooth deserves prompt evaluation even when symptoms are mild, but some warning signs raise the level of concern. These are the moments when delaying care can cost you both comfort and treatment options.

1. Pain wakes you at night or starts without eating or drinking.
2. Cold sensitivity lingers for more than a few seconds after the trigger is gone.
3. The tooth hurts sharply when you bite down or when you release pressure.
4. Part of the tooth feels loose, or your bite suddenly feels uneven.
5. Swelling, a bad taste, or gum tenderness develops near the injured tooth.

Each of these signs suggests something beyond a tidy enamel nick. Lingering sensitivity can point to Emergency Dentist Santa Clarita, CA pulpal irritation. Pain on release often raises suspicion for a crack. Swelling and bad taste may signal infection or bacterial contamination in a broken tooth. A change in bite means the remaining structure may be under abnormal stress every time you chew.

Why waiting can make the repair more complicated

Many people put off the visit because they are busy, because the tooth only hurts a little, or because they are hoping the sensitivity will settle down. Sometimes it does. But the underlying mechanics do not improve on their own. Teeth do not regrow chipped enamel, and a fractured cusp does not knit back together. What usually happens is continued flexing under bite pressure.

A rough example helps. Picture a molar with one cracked corner after biting down on an unpopped kernel. On day one, the piece is still attached and only sensitive to cold. By day four, that corner has flexed hundreds or thousands of times under chewing pressure. Bacteria have had repeated access to the exposed dentin. Now the tooth hurts on bites, the crack has spread deeper, and the restoration needed is larger and more expensive than it would have been earlier.

There is also the soft tissue issue. Sharp edges can repeatedly cut the tongue or cheek. It sounds minor until you have a patient with a painful ulcer from a jagged premolar edge scraping the same spot for three days. Smoothing and sealing the tooth early would have prevented a second problem entirely.

Children, teens, and sports injuries need a slightly different response

When a child or teenager chips a tooth, the emotional tone can be very different. There may be tears, visible bleeding from the lip, and a parent trying to sort out whether this is a dental emergency or something that can wait. If a permanent tooth is involved, especially a front tooth, prompt evaluation is wise. Younger teeth can behave differently after trauma because the nerve response and root development may still be evolving.

A chipped baby tooth can also deserve attention, particularly if the child is in pain, the edge is sharp, or the injury may have affected the developing permanent tooth underneath. The treatment priorities are not identical to adult care, but the need for assessment is real.

Sports injuries add another layer. Even when the chip seems clean and small, there may be associated trauma to the root, supporting bone, or temporomandibular joint. That is one reason mouthguards matter so much in

contact sports and even in activities people do not always think of as high risk, like skateboarding or mountain biking. The cost of a custom mouthguard is small compared with the cost and inconvenience of repairing a traumatized front tooth over many years.

Cosmetic concern is legitimate, even when the tooth is stable

It is easy to talk only about pain and structural damage, but appearance matters too. A chipped front tooth can make someone avoid smiling, postpone photos, and feel self-conscious in professional settings. That is not vanity. Teeth sit at the center of facial expression. When a visible tooth breaks, the impact can feel immediate and personal.

The good news is that modern repairs can often look very natural. Composite bonding is versatile for many small to moderate anterior chips. In some cases, porcelain veneers or crowns offer better shape control and stain resistance, especially if the tooth already had prior cosmetic work or significant damage. The right choice depends on the extent of the break, the neighboring teeth, the bite, and the patient's long-term goals.

A thoughtful emergency dentist will balance speed with aesthetics. Sometimes the best approach is a same-day provisional repair to restore appearance and comfort, followed by a more refined final restoration after the tooth has been fully evaluated and any inflammation has settled.

What to expect during an emergency visit in Santa Clarita

One reason people hesitate to call is that they are unsure what the appointment will involve. Most emergency dental visits for a chipped tooth start with a conversation, an exam, and imaging if needed. The dentist will identify the source of pain, test the tooth's response, inspect the bite, and look for hidden cracks or old restoration failure.

From there, the visit usually moves in one of two directions. The first is definitive treatment that same day, such as smoothing a sharp edge, placing bonding, repairing a filling, or protecting the tooth with a sedative or temporary material. The second is stabilization followed by a planned return for a crown, root canal, or more extensive reconstruction. Which path makes sense depends on what the exam shows and how symptomatic the tooth is.

Patients often appreciate directness here. A clear explanation beats false reassurance. If the nerve may declare itself over the next few days, it is better to hear that plainly. If the tooth is restorable but needs a crown because the remaining walls are too thin for a simple filling, that should be explained in practical terms. The goal is not just to stop the immediate problem but to choose a repair with a reasonable chance of lasting.

If you are searching for an **Emergency Dentist Santa Clarita, CA** families can rely on, it helps to look for a practice that offers prompt scheduling, experience with urgent restorative care, and the ability to coordinate follow-up treatment rather than leaving the repair half finished.

The role of old dental work in chipped teeth

A surprising number of chipped teeth are not pristine natural teeth that suddenly failed. They are teeth with history. Maybe there is a large silver filling from twenty years ago. Maybe the tooth has a bonded filling that has been replaced twice. Maybe a crown margin has begun to leak, or decay has undermined a cusp next to the restoration.

This matters because repairing the visible chip may only address part of the problem. Old restorations can hide cracks. Recurrent decay can weaken tooth walls until they crumble under normal chewing force. A filling that keeps getting larger each time it is replaced often reaches a point where a crown is simply more protective.

Patients sometimes feel frustrated when they came in for a “small chip” and leave hearing about a crown. But this is often less about overtreatment and more about biomechanics. A patch is only as strong as the tooth holding it. If the tooth has thin, unsupported enamel and multiple compromised walls, a full-coverage restoration may be the more conservative long-term decision because it prevents a larger failure later.

Insurance, cost, and practical decision-making

Cost is a real concern in emergency dentistry, and pretending otherwise does not help anyone. The price range for chipped tooth treatment varies widely because the category includes everything from simple smoothing to complex rehabilitation. A minor cosmetic repair is a different financial decision than root canal therapy and a crown.

A responsible way to approach this is to separate immediate need from final ideal treatment. If the tooth is painful, sharp, or vulnerable to further breakage, the first priority is stabilization and diagnosis. In many cases, a dentist can provide a protective interim step while discussing longer-term options. That can buy time for insurance verification, scheduling, or budgeting without leaving the tooth unprotected.

It is also worth asking what happens if treatment is delayed. Sometimes the cost of waiting is not just discomfort. It can be the difference between keeping a tooth with a straightforward restoration and losing enough structure that replacement options become necessary. Seen that way, prompt emergency care is often the more economical path.

Aftercare once the tooth has been repaired

Once the immediate problem is addressed, a little discipline goes a long way. A newly bonded front tooth is not a bottle opener or a tool for tearing tape. A temporarily restored molar should not be tested with hard nuts or sticky candy. If grinding contributed to the break, a nightguard may be part of the long-term solution, not an optional add-on.

Sensitivity after treatment is not unusual, especially if the chip was deep or the tooth took a hard impact. What matters is the pattern. Mild tenderness that improves is expected in many cases. Worsening pain, swelling, persistent throbbing, or bite discomfort that does not settle should trigger a call back to the office.

Good repair work and good habits reinforce each other. Even a beautifully restored tooth can fail if the underlying stressors, such as clenching, decay, or bite imbalance, are left untouched.

When the smartest move is simply to pick up the phone

People spend a lot of time online trying to decide whether their chipped tooth “counts” as an emergency. If there is one practical takeaway, it is this: you do not need to settle that question by yourself. The safer choice is to call and describe what happened. A trained team can usually tell from a few details whether you need same-day care, prompt next-day attention, or a routine visit.

If the tooth is painful, sharp, visibly broken, temperature-sensitive, or affecting your bite, the answer is usually not to wait. A quick evaluation by an **Emergency Dentist Santa Clarita, CA** patients trust can mean less pain, a more conservative repair, and a better chance of saving the natural tooth. With chipped teeth, small windows often

matter. Acting early gives the dentist more to work with, and it gives you a much better chance of putting the whole episode behind you quickly.

Smyle Dental Newhall
23754 Newhall Ave
Santa Clarita, CA 91321, United States
+16612559200

FAQ About Emergency Dentist Santa Clarita, CA

Will the ER do anything for dental pain?

An emergency department can assess serious complications and provide temporary care, but it usually cannot provide definitive dental treatment such as a filling or root canal. A dentist needs to identify and treat the cause. Call 911 or seek emergency medical care for difficulty breathing or swallowing, major facial injury, or uncontrolled bleeding.

What qualifies as a dental emergency?

A knocked-out permanent tooth, severe or persistent dental pain, swelling, and a broken tooth with pain need prompt professional assessment. Contact a dentist immediately for guidance on how urgently to be seen. Rapidly spreading swelling or swelling that affects breathing or swallowing requires emergency medical care.

What to do if I have a dental emergency in the middle of the night?

Call your dentist's office for after-hours instructions. Smyle Dental Newhall can be reached at (661) 255-9200; confirm when treatment is available. Do not wait for the office to open if you have trouble breathing or swallowing, uncontrolled bleeding, or a major facial injury. For a toothache while arranging dental care, gently rinse with warm water and avoid putting aspirin directly on the tooth or gums.